Treatment of a Club Member with fragile skin

The Lindsay LegClub Foundation

Mrs P is a 69-year old, very sociable lady, who has been unfortunately widowed for some time. She has never smoked cigarettes and is well nourished with a healthy appearance.

In 2011, Mrs P developed a leg ulcer, which stubbornly refused to heal and this kept her at home and reduced her quality of life.

Her Doppler assessment showed that the ankle brachial pressure index was within normal limits and so her arteries were patent and compression bandaging was applied.

The wounds would heal but almost immediately break down again. The slightest touch on the skin and a wound would develop. Applying hosiery was extremely difficult as pulling on the hosiery would tear the skin. This is due to the fragility of the epidermal-dermal junction.

Epidermal-dermal junction

The skin is an organ, the largest in the body and is just as important as the kidneys and liver etc. It covers the entire external surface of the human body and is the principal site of interaction with the surrounding world. It serves as a protective barrier that prevents internal tissues from exposure to trauma, ultraviolet (UV) radiation, temperature extremes, toxins, and bacteria. Other important functions include sensory perception, immunologic surveillance, thermoregulation, and control of insensible fluid loss.

Damage to the skin can be life threatening and so it is vital to keep layers of the skin healthy. However, as we age, the skin 'thins' due to loss of collagen and wear and tear and would then require greater vigilance in protecting the skin surface. Skin tears become more likely and this is due to the interaction of the epidermal and dermal junction. The epidermal-dermal junction holds the epidermis and dermis together with finger like projections or protrusions of dermal papillae (*Figure 1*) and these projections are achieved with various fibres including collagen (Shukla et al, 2015). These projections firmly link the two layers together and hold them tight. As we age, these two layers become less firmly linked and the finger-like projections can begin to flatten making skin tears more likely. Also, in some young people with epidermolysis bullosa, it is this junction that separates, causing the blistering condition. The epidermis is the relatively thin, tough, outer layer of the skin that is a separate layer from the dermis and does not contain blood vessels and the finger like projections also provides an increased surface area for the exchange of oxygen and nutrients between the two sections.

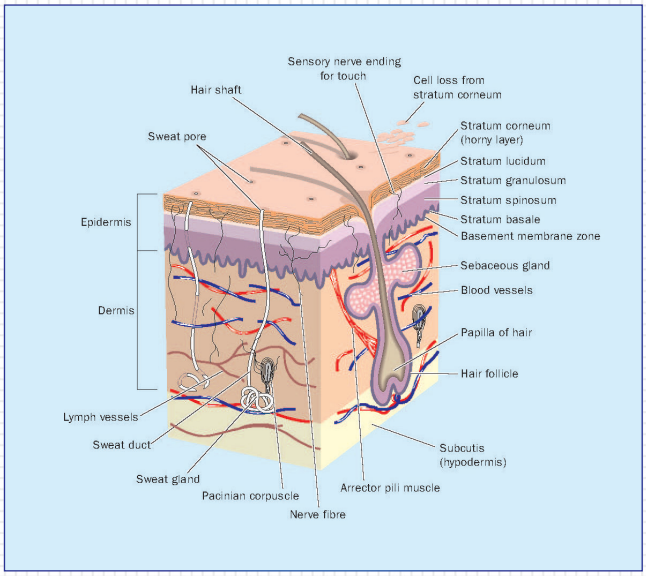

Figure 1. Epidermal-dermal junction

The layers of the epidermis are continually moving upward, flattening, building up at the surface and then eventually sloughing off to make room for the cells from behind them. This natural movement or "keratinisation" of the skin is an integral part of skin renewal and healing. It would not be possible without the epidermal-dermal junction maintaining a healthy relationship with the dermis.

The dermis is the layer beneath the epidermis and is a thick layer of fibrous and elastic tissue (made mostly of collagen, elastin, and fibrillin) and is usually seen when a blister 'deroofs' leaving a shiny and red surface that rarely bleeds. The relationship between these two main layers of skin,

Annamarie Ivory, Katie Bennett, Hayley Mepstead, Sylvie Hampton

Sylvie Hampton, Independent Wound Care Consultant Nurse

Sylvie.hampton@legclubfoundation.com

Figure 2. Mrs P's fragile skin

Figure 3. Toe bandaging to reduce toe swelling

allows for healthy communication from the top all the way to the bottom. When the two layers reduce the ability for the finger like projections to hold together, then the skin becomes fragile and easily damaged, as in the case of Mrs P.

Treatment of Mrs P

Mrs P would have her legs washed in a bucket of warm water at 37 degree temperature. Her leg skin is fragile (*Figure 2*) and great care has to be taken in handling. Also, Mrs P's toes are slightly swollen, possibly pre lymphoedema, toe bandages are required (*Figure 3*).

Any adhesive dressing would adhere to the skin and tear the epidermal-dermal junction apart. Therefore, Icthopaste (*Figure 4*) was applied as this is ideal for fragile or eczema skin and would not adhere to the epidermis.

Application of compression hosiery was attempted but failed due to the damage caused when applying them. A solution to this may be silk hosiery (DermaSilk) as these can be applied under hosiery and will not cause any trauma. The compression hosiery can then be safely applied over the silk hosiery.

Mrs P is pleased to be a Member of the Leg Club as it provides her with a social outlet among others with similar problems. She says she cannot fault the care provided to her and the nurses are wonderful. She is grateful as she now has no pain and can begin to regain some quality of life. CWC

Figure 4. Icthopaste

Shukla A, Dey N, Nandi P, Ranjan M (2015) Acellular Dermis as a Dermal Matrix of Tissue Engineered Skin Substitute for Burns Treatment. *Ann Public Health Res* **2**(3): 1023

Stücker M, Struk A, Altmeyer P, Herde M, Baumgärtl H, Lübbers DW (2002) The cutaneous uptake of atmospheric oxygen contributes significantly to the oxygen supply of human dermis and epidermis. *J Physiol* **538**(3): 985–994.