

Diabetic foot ulcers

An algorithm for assessment and dressing selection

Mölnlycke®

Holistic foot ulcer managem

Assessment of patients and their feet

1 Medical history

- Physical, physiological and psychosocial health

2 Feet inspection

- Callus, cracks
- Colour, erythema
- Temperature
- Dry skin
- Eczema
- Oedema of feet/lower legs
- Deformities e.g. Charcot foot (need for x-ray/MRI)
- Previous amputations
- Gangrene
- Inspecting nails and between the toes

3 Neuropathy

- **Motor neuropathy** (deformities)
- **Sensory neuropathy** (loss of sensation and vibration. Tests with 10g Monofilament or Ipswich Touch Test and tuning fork)
- **Autonomic neuropathy** (dry skin, cracking skin, callus)

4 Vascular status and oxygenation levels

- Palpation of peripheral pulses: femoral, popliteal and pedal (dorsalis pedis and posterior tibial) pulses
- Doppler assessment and ABPI
- Toe-brachial index (TBI)
- Potential referral to a specialist for a full vascular assessment
- Consider oxygen assessment e.g. with transcutaneous oximetry ($TcPO_2$)

5 Wound and periwound

Infection:
Local signs of infection can be: increased exudate, non-healing, malodour, friable or discoloured granulation tissue, redness, pain, heat and swelling. If osteomyelitis is suspected, or an active spreading infection, refer to a multidisciplinary footcare team immediately.

Wound bed, status/colour:

- Black necrotic tissue
- Yellow slough
- Red granulation tissue, pink epithelialisation

Depth

Exudate

- Amount (none, low, moderate, high)
- Consistency/colour

- **Wound location**
- **Wound size (area/depth)**
- **Wound edge** (raised edge, undermining/tracks/ sinuses)
- **Surrounding skin** (maceration/excoriation, erythema, oedema)
- **Exposed bones, tendons, joint capsules or orthopaedic implants**
- **Pain** (location, frequency, cause, type, intensity and duration)
- **Odour** (presence and nature)

6 Classification

e.g. WIfI, University of Texas, Wagner, PEDIS or SINBAD

Goals of treatment, education and concordance with the patient

60-second Diabetic Foot Screen
a Screening tool (2018).[1]

Management of DFU[2]

A patient with a diabetic foot ulcer (DFU) or at risk of developing a DFU needs to be referral to a multidisciplinary footcare team (MDFT). They can provide with e.g.

- Offloading wound and risk areas with specialist foot wear.
- Full vascular assessment.
- Oedema treatment.
- Infection control and treatment.
- Wound debridement/cleansing and treatment recommendation.
- Nutritional advice.
- Optimal diabetes control.

Remember:

- Assess and manage pain (local and systemic) before dressing changes.
- Be aware of the arterial blood supply. If dry black necrosis – keep dry and refer for a full vascular assessment.
- Moisturize lower extremities and feet daily. Do not put lotion between toes.
- Educate on self-treatment for healthy feet.

For complete and updated assessment and management guidance please visit International Working Group on the Diabetic Foot (IWGDF) www.iwgdfguidelines.org

Be aware of systemic infection symptoms:

- Fever
- Rigour
- Chills
- Hypotension
- Multi-organ failure

Read more at:
www.mdcalc.com/sirs-sepsis-septic-shock-criteria

These recommendations are aligned with the International best practice guidelines: IWGDF practical guidelines on the prevention and management of diabetic foot disease, 2019.

ent in patients with diabetes

Mölnlycke® dressing selection guide

	Requirement for antimicrobial*			**No** requirement for antimicrobial		
Infection						
Wound bed	Black dry Necrosis	Red or Yellow **Topical oxygen therapy with Granulox®		Black dry Necrosis 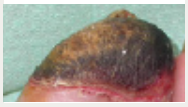	Red or Yellow **Topical oxygen therapy with Granulox®	
Depth		Cavity	Superficial 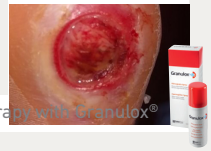 **Topical oxygen therapy with Granulox®		Cavity **Topical oxygen therapy with Granulox®	Superficial 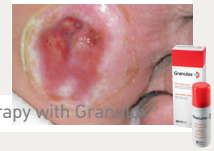
Exudate level	Mepilex® Transfer Ag	Cavity	Superficial	Mepitel® One	Cavity	Superficial
		Exufiber® Ag+ + Mepilex® Lite	Mepilex® Ag		Exufiber® + Mepilex® Lite	Mepilex® Lite or Mepilex® XT
		Exufiber® Ag+ + Mepilex® Border Flex	Mepilex® Border Ag		Exufiber® + Mepilex® XT or Mepilex® Border Flex	Mepilex® Border Flex
		Exufiber® Ag+ + Mextra® Superabsorbent	Mepilex® Transfer Ag + Mextra® Superabsorbent		Exufiber® + Mextra® Superabsorbent	Mepilex® Transfer + Mextra® Superabsorbent

If ulcer size has not reduced by more than 50% by 4 weeks reassess and refer to a MDFT or consider other/advanced technologies[2-4].

** Topical oxygen therapy (TOT) with Granulox® is suitable for patients at high risk of delayed wound healing[5].

* For infected DFUs (see picture), aggressive debridement, topical antiseptics and systemic antibiotics are generally recommended. Active spreading infection must be referred as a matter of urgency to a MDFT. Topical antimicrobial agents, e.g. in cleansers or dressings, may be used in combination with antibiotics to treat mild infections. Such dressings or cleansers may also be used alone to treat DFUs which are highly at risk of developing infections.[2,6]

!

- Optimal wound management with provision of local treatment need to be supported with appropriate management of systemic disease, pressure offloading and debridement. Remember that surgical debridement is contraindicated if ischaemia is present[4]
- Monitor at each dressing change and reassess regularly. Be sure that the dressing is compatible with shoes and other offloading therapies and can be accommodated without bulk and creasing
- If you need to cut the dressing, consider using non-bordered products
- For fixation, consider using Tubifast®
- If you need to dress a toe, consider using Mepitel® One or Mepilex® Lite for good conformability
- The choice of dressings must be based on local protocols and clinical judgement

Proven choice for a better outcome

Safetac® is the original less-pain contact layer with silicone adhesion. We designed it to mould softly to skin without sticking to the moist wound[7] – so you can remove it easily without damaging the skin[8]. That means less pain for your patients[9].

Safetac also protects new tissue and intact skin – so wounds remain undisturbed to support faster natural healing[10-13]. And it seals the wound margins to protect skin from damaging leaks and maceration[14,15]. This combination of less pain[9] and less skin damage[8,11-14,16] – to support faster healing[10-13] – can also reduce the cost of treatment[11,12,16].

You can trust Mölnlycke® dressings with Safetac, for better patient and economic outcomes.

Safetac® TECHNOLOGY

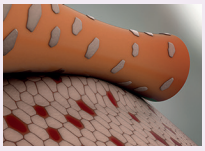

Skin stripping occurs with traditional adhesive[8]

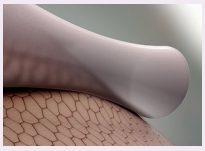

No skin stripping occurs with Safetac technology[8]

Dressing information

Mepitel® One

- Soft silicone wound contact layer
- For dry to highly exuding wounds
- Highly transparent for quick and easy wound inspection
- Can remain in place for up to 14 days depending on the wound condition[17]
- Minimises skin damage and pain at dressing changes[10,11,17]

Mepilex® Lite

- Light foam dressing with soft silicone wound contact layer
- For non to low-exuding wounds; designed to maintain a moist wound environment
- Thin, soft, and highly conformable
- Can easily be cut to size
- Minimises pain and damage at dressing change[9]

Mepilex® XT
Mepilex® Ag

- Foam dressings with soft silicone wound contact layers with (Mepilex Ag) and without silver (Mepilex XT)
- For low to moderately exuding wounds, designed to maintain a moist wound environment
- Soft and conformable foam dressing
- Can easily be cut to size
- Mepilex XT can handle both low and high viscosity fluid[18]
- Mepilex Ag kills wound-related pathogens within 30 minutes; and carries on doing so for up to 7 days (*in vitro* studies)[19]
- Minimise skin damage and pain at dressing changes[9]

Mepilex® Border Flex

- All-in-one bordered foam dressing with flex cuts
- For moderately to highly exuding wounds; designed to maintain a moist wound environment
- Enables 360 degree stretch to enhance stay-on-ability and conformability[20-23]
- Contains superabsorbent fibres for high absorption and retention[24]
- Minimise skin damage and pain at dressing changes[9,24]

Mepilex® Border Ag

- All-in-one bordered foam dressing containing silver
- For moderately to highly exuding wounds; designed to maintain a moist wound environment
- Combines excellent exudate management properties with antimicrobial action[25,26]
- Minimise skin damage and pain at dressing changes[9]

Exufiber®

- Gelling fiber dressing
- Transforms into a gel that provide a moist wound environment[27,28]
- High tensile strength to enable dressing removal in one piece[28]
- Absorbs and retains exudate, blood and bacteria[28]
- Soft and conformable which make it easy to apply[27]

Exufiber® Ag+

- Gelling fibre dressing containing silver
- Transforms into a gel and softly conforms to the wound bed[29,30]
- For moderately to highly exuding wounds
- The Hydrolock® Technology absorbs and locks in exudate, blood and bacteria. The high structural integrity enables one-piece dressing removal[31-36]
- Silver kills a broad range of pathogens (*in vitro*) and reduce biofilm, the antimicrobial effect is kept for up to seven days (*in vivo*)[37-39]
- Can easily be cut and used in cavities

Mepilex® Transfer
Mepilex® Transfer Ag



- Exudate transfer dressings with (Mepilex Transfer Ag) and without silver (Mepilex Transfer)
- Effectively transfer exudate to a secondary layer[40]
- Very thin and conformable foam for difficult-to-dress locations
- Can easily be cut to size
- Mepilex Transfer Ag inactivates a broad range of microorganisms (*in vitro* studies)[41]
- Mepilex Transfer Ag combines a rapid antimicrobial effect within 30 min and a sustained effect up to 14 days (*in vitro* studies)[41]
- Minimise skin damage and pain at dressing changes[9,42]

Mextra® Superabsorbent

- Superabsorbent dressing with fluid-repellent backing
- For highly exuding wounds
- Superabsorbent particles for high absorption and retention[43]
- Soft and conformable
- Fluid repellent backing layer protects against fluid strike-through

Tubifast®

- Tubular retention bandage
- Holds dressings securely, without constriction or compression
- A variety of lengths are available
- Available in a range of quick reference, colour-coded sizes to fit everything from small limbs to adult trunks

Granulox®

- Topical haemoglobin-based spray
- The haemoglobin spray acts by facilitating the diffusion of oxygen from the atmosphere into the wound bed
- Time to heal diabetic foot ulcers 50% shorter than with standard of care[44]
- Granulox® is easy to handle and to apply

Please note: This guide is not comprehensive and the reader should always refer to local guidelines.

References: **1.** INLOW's 60-second Diabetic Foot Screen. Screening tool. Canadian Association of Wound Care. www.cawc.net. 2011. https://guidelines.diabetes.ca/docs/resources/Inlows-60-second-diabetic-foot-screen-Wounds-Canada.pdf. 2018. **2.** World Union of Wound Healing Societies (WUWHS). Florence Congress. Position Document. Local Management of Diabetic Foot Ulcers. Wounds International 2016. Available at: http://www.woundsinternational.com (Accessed 8 November 2018). **3.** Frykberg, R.G., Banks, J. Challenges in the treatment of chronic wounds. Adv Wound Care (New Rochelle) 2015;4:560-82. **4.** Ousey, K., Chadwick, P., Jawien, A., et al. Identifying and treating foot ulcers in patients with diabetes: saving feet, legs and lives. J Wound Care 2018;27 (Suppl 5):S1-S52. **5.** Chadwick, P.M., McCardle, J., Luxmi, M., et al. Appropriate use of topical haemoglobin in chronic wound management: consensus recommendations. Wounds UK 2015;EWMA Special: 30–35. **6.** International Best Practice Guidelines. Wound Management in Diabetic Foot Ulcers. Wounds International 2013. Available at: http://www.woundsinternational.com (Accessed 8 November 2018). **7.** White R. Evidence for atraumatic soft silicone wound dressing use. Wounds UK 2005;1(3):104-109. **8.** Waring, M., Biefeldt, S., Matzold, K.P., Butcher, M. An evaluation of the skin stripping of wound dressing adhesives. J Wound Care 2011;20:412-22. **9.** White, R. A multinational survey of the assessment of pain when removing dressings. Wounds UK 2008;4:14-22. **10.** David, F., Wutze, J-L., Breton, N., et al. A randomised, controlled, non-inferiority trial comparing the performance of a soft silicone-coated wound contact layer (Mepitel One) with a lipidocolloid wound contact layer (UrgoTul) in the treatment of acute wounds. Int Wound J 2017 doi:10.1111/iwj.12853. **11.** Gotschall, C.S., Morrison, M.I., Eichelberger, M.R. Prospective, randomized study of the efficacy of Mepitel on children with partial-thickness scalds. J Burn Care Rehabil 1998;19:279-83. **12.** Silverstein, P., Heimbach, D., Meites, H., et al. An open, parallel, randomized, comparative, multicenter study to evaluate the cost-effectiveness, performance, tolerance, and safety of a silver-containing soft silicone foam dressing (intervention) vs silver sulfadiazine cream. J Burn Care Res 2011;32:617-26. **13.** Gee Kee, E.L., Kimble, R.M., Cuttle, L., Khan, A., Stockton, K.A. Randomized controlled trial of three burns dressings for partial thickness burns in children. Burns 2015;41:946-55. **14.** Meaume, S., Van De Looverbosch, D., Heyman, H., Romanelli, M., Ciangherotti, A., Charpin, S. A study to compare a new self-adherent soft silicone dressing with a self-adherent polymer dressing in stage II pressure ulcers. Ostomy Wound Manage 2003; 49 (9): 44-51. **15.** Wiberg, A-B., Feili, F., Daun, E-K. Preventing maceration with a soft silicone dressing: *in vitro* evaluation. Poster presentation at the 3rd Congress of the World Union of Wound Healing Societies, Toronto, Canada, 2008. **16.** Bredow J, Hoffmann K, Hellmich M, Eysel P, Zarghooni K. Randomized clinical trial to evaluate performance of flexible self-adherent absorbent dressing coated with silicone layer after hip, knee or spinal surgery in comparison to standard wound dressing. Poster presentation at the 5th Congress of the World Union of Wound Healing Societies, Florence, Italy, 2016. **17.** Patton, M.L., Mullins, R.F., Smith, D., Korentager, R. An open, prospective, randomized pilot investigation evaluating pain with the use of a soft silicone wound contact layer vs bridal veil and staples on split thickness skin grafts as a primary dressing. J Burn Care Res 2013;34:674-81. **18.** Mölnlycke Health Care data on file, report 20160105-002. **19.** Chadwick, P., Taherinejad, F., Hamberg, K., Waring, M. Clinical and scientific data on a silver-containing soft-silicone foam dressing: an overview. J Wound Care 2009;18:483-91. **20.** ProDerm study report 16.0180-23. Assessment of Wearing Properties of Wound Dressings on the Knees. Data on file. **21.** ProDerm study report 16.0180-23. Assessment of Wearing Properties of Wound Dressings on the Elbows. Data on file. **22.** ALTEN Finite Element Modelling simulation. Laboratory report no .PD-530246. **23.** Haycocks, S., Chadwick, P., Davies, P. Case series: Mepilex Border Comfort in the treatment of diabetic foot ulcers with exudate. Diabetic Foot Journal 2018;21:265-71. **24.** External test lab report SMTL15/4863/2. **25.** External lab report: NAMSA 09C 29253 01/09C 29253 02. **26.** Kles C.L., Murrah, C.P., Smith, K., et al. Achieving and sustaining zero. Preventing surgical site infections after isolated coronary artery bypass with saphenous vein harvest through implementation of a staff-driven quality improvement process. Dimensions Crit Care Nurs 2015;34:265-72. **27.** Smet, S., Beele, H., Saine, L., Suys, E., Henrickx, B. Open, noncomparative, multi-centre post market clinical follow-up investigation to evaluate performance and safety on pressure ulcers when using a gelling fibre dressing as intend-ed. Poster Presentation at European Pressure Ulcer Advisory Panel Confer-ence, 2015, Ghent, Belgium. **28.** Chadwick P, McCardle J. Open, non-comparative, multicentre post clinical study of the performance and safety of a gelling fibre wound dressing on diabetic foot ulcers. J Wound Care 2016;25:290-300. **29.** Davies P, McCarty S. An in-use product evaluation of a gelling fibre dressing in wound management. E-poster presentation at Wounds UK Conference, 2017, Harrogate, United Kingdom. **30.** Lev-Tov et al. An interim analysis of clinical investigation to evaluate exudate management and comfort of use of an antimicrobial gelling fiber dressing* in medium to highly exudative wounds. Poster presented at the Symposium of Advanced Wound Care, Fall meeting 2018, Las Vegas, NV, USA. **31.** Mölnlycke Health Care Laboratory Report PD-521248 (unpublished). **32.** Mölnlycke Health Care Laboratory Report PD-556978 (unpublished). **33.** Mölnlycke Health Care Laboratory Report PD-520425 (unpublished). **34.** Mölnlycke Health Care Laboratory Report PD- 521232 (unpublished). **35.** Mölnlycke Health Care Laboratory Report PD- 522900 (unpublished). **36.** Mölnlycke Health Care Laboratory Report PD- 521245 (unpublished). **37.** Hamberg K et al. Antimicrobial effect of a new silver-containing gelling fibre dressing against common wound pathogens. Poster presented at the Symposium on Advanced Wound Care Spring meeting/ Wound Healing Society (WHS) Annual Meeting 2017, Apr 05–09, 2017, San Diego, CA, USA. **38.** Gil J et al. 2017. Evaluation of a Gelling Fiber Dressing with Silver to Eliminate MRSA Biofilm Infections and Enhance the Healing. Poster presented at the Symposium on Advanced Wound Care Spring meeting/ Wound Healing Society (WHS) Annual Meeting 2017, Apr 05–09, 2017, San Diego, CA, USA. **39.** Valdes et al. 2017. Evaluation of a Gelling Fiber Dressing with Silver to Eliminate P. a. Biofilm Infections and Enhance the Healing. Poster presented at the Symposium on Advanced Wound Care Spring meeting/Wound Healing Society (WHS) Annual Meeting 2017, Apr 05–09, 2017, San Diego, CA, USA. **40.** Grocott Patricia Clinical investigation Mepilex® Transfer, Clinical Investigation of a silicone dressing in product development phase in the palliative management of patients with pressure sores and malignant wounds, study id MIN101 UK, London UK,2000. **41.** External lab report; NAMSA 11C_51788_01. **42.** Meuleneire, F. Management of diabetic foot ulcers using dressings with Safetac: a review of case studies. Wounds UK 2008;4:16-30. **43.** Tickle, J., Fletcher, J. Mextra Superabsorbent made easy. Wounds UK 2012;8: 1-4. **44.** Hunt SD, Elg F. Clinical effectiveness of hemoglobin spray (Granulox®) as adjunctive therapy in the treatment of chronic diabetic foot ulcers. Diabetic Foot & Ankle 2016;7:33101.

Mölnlycke Health Care AB, Box 13080, Gamlestadsvägen 3C, SE-402 52 Göteborg, Sweden. Phone +46 31 722 30 00.

The Mölnlycke, Mepilex, Mextra, Tubifast, Exufiber, Mepitel, TwoWay Stretch, Granulox and Safetac trademarks, names and logotypes are registered globally to one or more of the Mölnlycke Health Care group of companies.
© 2019 Mölnlycke Health Care AB. All rights reserved. HQIM001114

Mölnlycke®