Doppler Assessment: A Practical Guide

Elaine Gibson BSc(Hons) DipN, RGN
Tissue Viability Vascular Nurse Specialist
East Kent University Hospitals Foundation Trust

Dr Jon Evans BSc PhD MIET CEng
Vascular Business Unit Manager
James Cashin BSc(Hons)
Product Specialist

Trudie Young RGN MSc
Facilitator

Conference workshops in association with the Leg Club Industry Partners

"Empowering patients through a unique collaboration with industry dedicated to lower limb conditions"

PATIENTS COMMUNITY DISTRICT NURSES
LEG CLUB®
www.legclub.org

Examination of the arterial patient

Clinical features of the ischaemic foot

Doppler Assessment

Doppler ABPI Measurements

Other useful tests

Pole Test

Doppler Waveforms and Sounds

Waveforms provide extra information to confirm clinical findings and ABPI's

Triphasic Waveform - Normal

Biphasic Waveform – Normal with age

Doppler Waveforms and Sounds

Monophasic Waveform - Abnormal

Toe Pressures

Doppler or Photoplethysmography (PPG)

- Toe/brachial pressure > 0.7 = normal
- Rest pain usually present in patients with index < 0.15
- Absolute pressure in the toes of 20-30mmHg is usually associated with rest pain

Problems with measuring ABPI using Doppler

Advantages of Auto ABPI

Pulse Volume Recordings

Pulse Volume Recordings

Grade A: Normal

Sharp systolic peak with prominent dicrotic notch

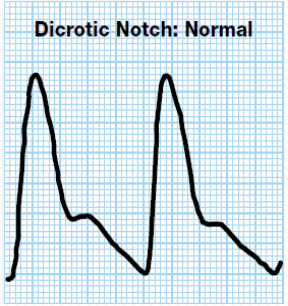

Grade B: Mildly Abnormal

Sharp peak, absent dicrotic notch; downslope is bowed away from baseline

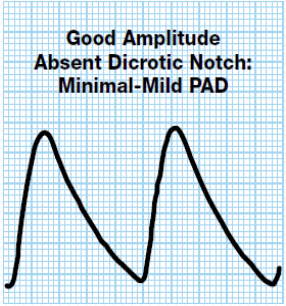

Grade C: Moderately Abnormal

Flattened systolic peak, upslope and downslope time decreased and nearly equal, absent dicrotic notch.

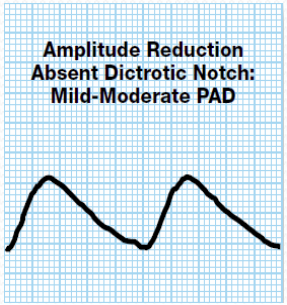

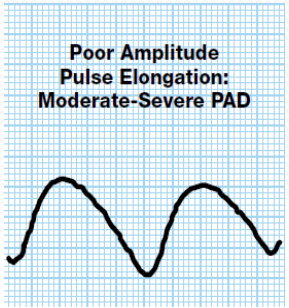

Grade D: Severely Abnormal

Low amplitude or absent pulse wave with equal upslope and downslope time

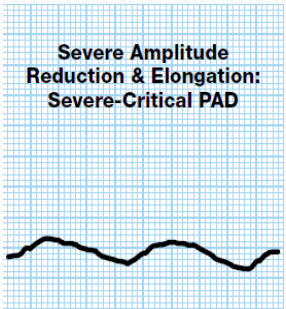

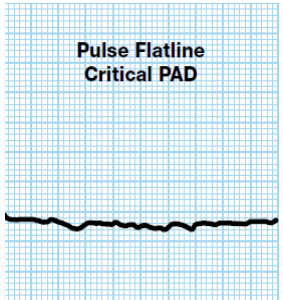

Recent Study (Lewis et al, 2014)

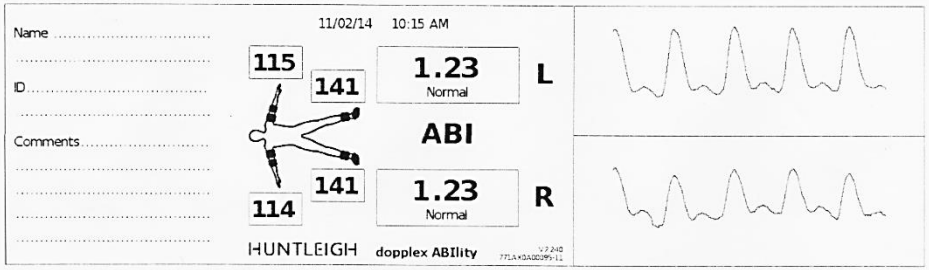



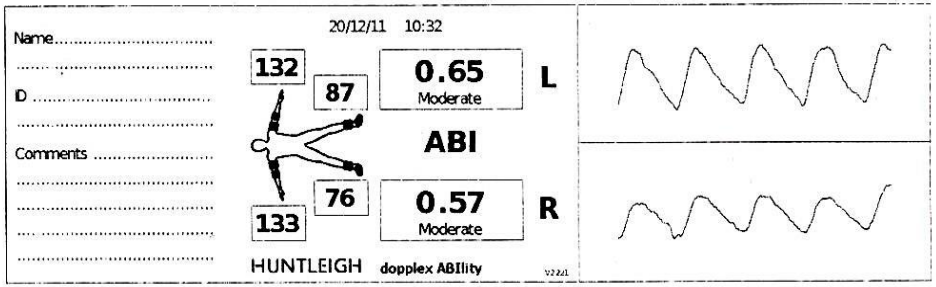

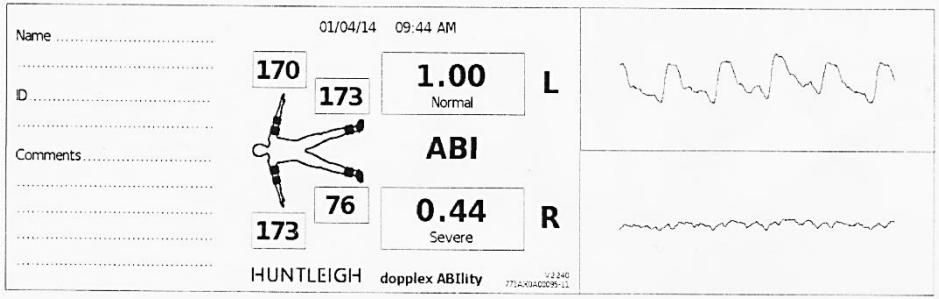

Examples of normal & mild disease

A) Both ABI and PVR waveforms indicate normal lower limb arterial supply

B) Left ABI and PVR waveform indicate normal lower limb arterial supply and right ABI and PVR waveform indicate mild PAD

Examples of moderate and severe disease

C) Both ABI and PVR waveforms indicate moderate PAD

D) Left ABI and PVR waveform indicate normal lower limb arterial supply and right ABI and PVR waveform indicate severe PAD

PATIENTS COMMUNITY DISTRICT NURSES LEG CLUB® www.legclub.org

Recent Study

(Davies et al, 2014)

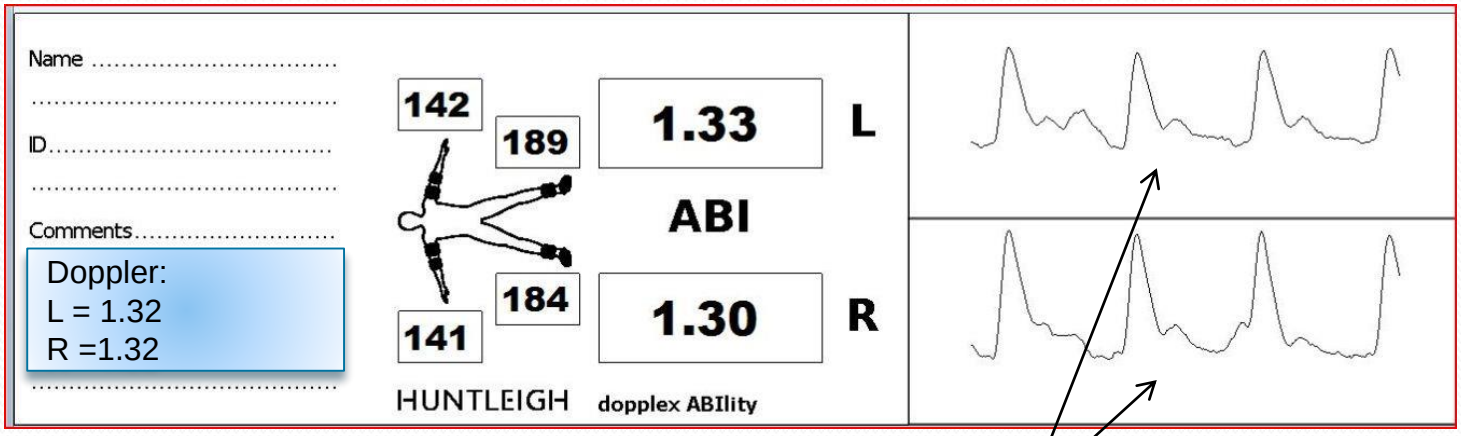

Normal Pulse Volume Recording

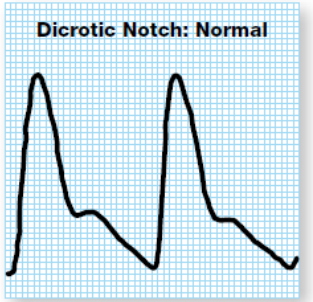

PATIENTS COMMUNITY DISTRICT NURSES
LEG CLUB®
www.legclub.org

Recent Study

(Davies et al, 2014)

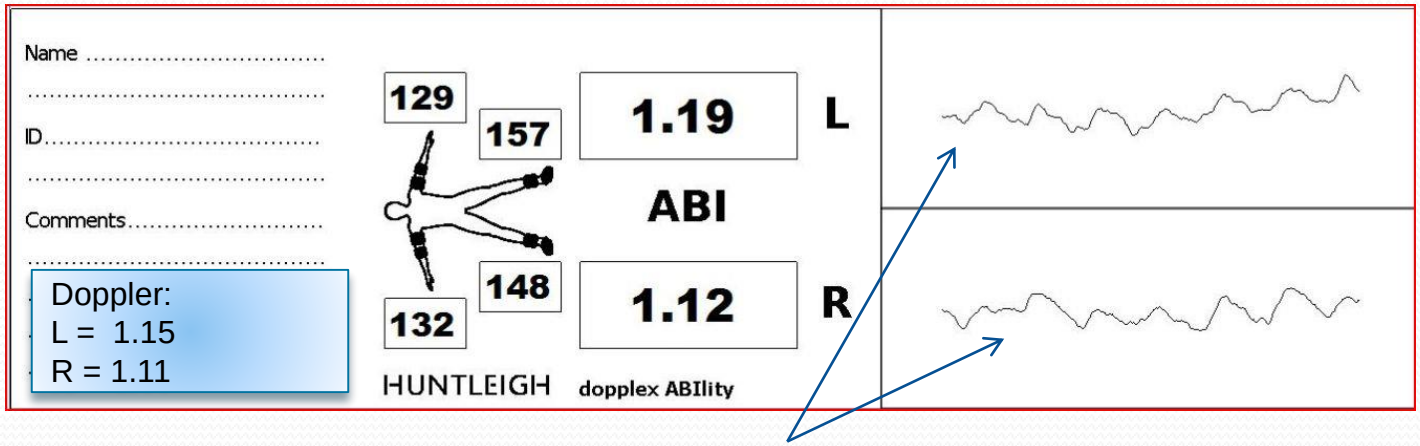

Analysis of pulse volume waveform?

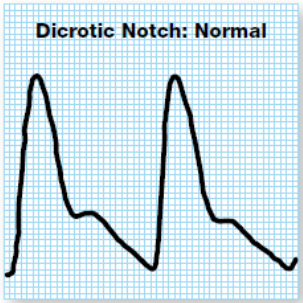

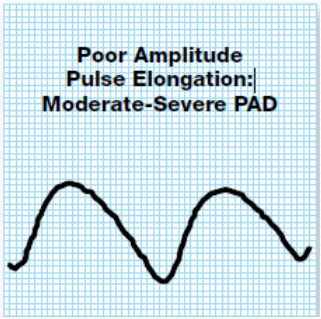

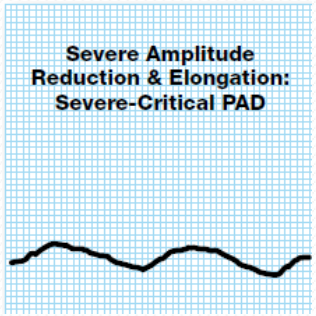

RESULT: Moderate-severe PAD. Referred to vascular surgeon. Subsequently underwent successful angioplasty.

Thank You
Any Questions